

Split Hump Technique for Reduction of the Overprojected Nasal Dorsum

A Statistical Analysis on Subjective Body Image in Relation to Nasal Appearance and Nasal Patency in 97 Patients Undergoing Aesthetic Rhinoplasty

Peter J. F. M. Lohuis, MD, PhD; Sara Faraj-Hakim, MD; Arno Knobbe, PhD; Wouter Duivesteijn, MSc; Gregor M. Bran, MD

Objectives: To describe the split hump technique (SHT) and to examine its effectiveness for correction of an overprojected nasal dorsum in patients undergoing aesthetic rhinoplasty.

Methods: This prospective study included 97 patients. Objective assessment was performed using a short, practical questionnaire. Investigation focused on nasal patency and the patient perception of body image in relation to nasal appearance using 5-point Likert scale questions and visual analog scales.

Results: Use of the SHT resulted in a significant improvement in nasal patency and aesthetic nasal perception. Sum functional question scores decreased from 9.154 to 6.351 and aesthetic question scores from 13.897 to 6.825 ($P < .001$ for both). Mean aesthetic visual analog scale scores improved in all patients, from 3.346 to 7.782 ($P < .001$). Graphic illustration of this improvement re-

vealed a gaussian curve of normal distribution around a mean (SD) improvement of 4.48 (1.93).

Conclusions: Traditional en bloc humpectomy maneuvers are frequently combined with spreader graft use to avoid postoperative inferomedial repositioning of the upper lateral cartilages and inverted-V deformity. The SHT for correction of the overprojected dorsum creates a paradigm change in this patient group. The transverse segments of the upper lateral cartilages are saved and repositioned instead of being resected as a part of an en bloc osseocartilaginous composite hump resection in a transverse plane. Several modifications of the SHT enable the surgeon to deproject the nose while keeping sufficient strength in the keystone area and augmenting dorsal width. Using statistical analysis of subjective patient data, we could prove a broad acceptance and appreciation for the SHT.

Arch Facial Plast Surg. 2012;14(5):346-353

MOST WHITE AND MEDITERRANEAN patients who undergo aesthetic rhinoplasty report wanting to correct a noticeable hump in profile view. This makes adequate reduction of a prominent dorsum a major determinant of success in these patients. Traditional hump reduction maneuvers are based on en bloc resection in a transverse plane, removing the dorsal hump as an osseocartilaginous composite (**Figure 1**). This method includes excision of the transverse component of the upper lateral cartilages (ULCs), which is often associated with a delicate impairment of the stability in the keystone area (K-area).¹ Destabilization of the K-area triggers inferomedial repositioning of the ULCs, resulting in a conspicuous inverted-V deformity (**Figure 2**). The

appearance of this deformity can be aggravated by overresection of the osseocartilaginous dorsum, especially in patients with short nasal bones (**Figure 3** and **Figure 4**).

To avoid the complications associated with inclining ULCs after traditional humpectomy, surgeons have established the importance of using spreader grafts or their variations since the 1980s. Submucosal placement of individually fashioned strips of cartilage along the anterior border of the septal dorsum bridges the gap of the open roof, thereby maintaining the horizontal relationship between the septum and the ULCs. Subsequently, inferomedial repositioning of the ULCs can effectively be avoided, and the function of the internal valve can be preserved.²⁻⁶

The preventive benefit of using spreader grafts or their variations is not the only

Author Affiliations:
Department of Otolaryngology/Head and Neck Surgery, Center for Facial Plastic and Reconstructive Surgery, Diaconessen Hospital Zeist, Zeist (Drs Lohuis, Faraj-Hakim, and Bran); and Leiden Institute of Advanced Computer Science, Leiden University, Leiden (Drs Knobbe and Duivesteijn), the Netherlands.

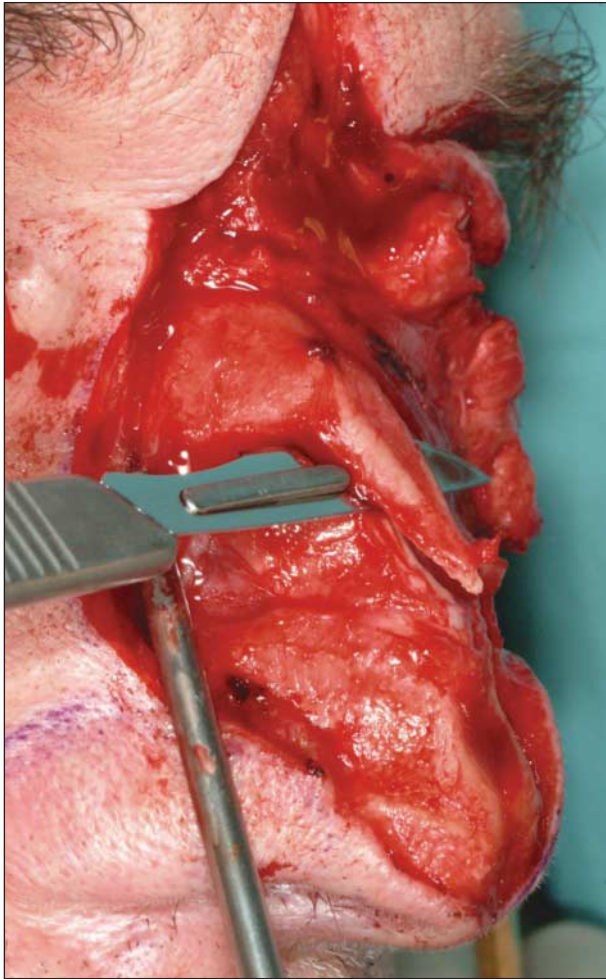


Figure 1. Intraoperative view of a 3-layer resection of the nasal dorsum as an osseocartilaginous composite using a No. 10 blade to lower the dorsum. The resection was performed as an adjuvant procedure in a patient with skin cancer, but this intraoperative view permits clear visualization of a traditionally performed en bloc hump resection maneuver, which is also schematically visualized in Figure 2.

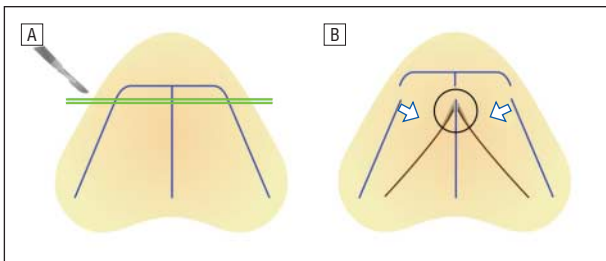


Figure 2. A, Schematic illustration of the transverse en bloc hump resection maneuver using a No. 10 blade (the plane of dissection is marked by a green double line). The transverse components of the upper lateral cartilages (ULCs) are completely removed, leading to an open roof deformity. B, This results in a loss of structural support on both sides of the septum. Destabilization of the junction between the ULCs and the septum leads to an inferomedial repositioning of the ULCs (vectors of pull are indicated by arrows). The inclining lateral components are of insufficient length for bridging the gap. Consequently, a distinct shade formation unfolds (marked by the circle), which can clinically be identified as an inverted-V deformity. The en bloc resection technique leads to a reduction in dorsal height and to an unpredictable reduction in dorsal width.

concept that ensures avoidance of inverted-V deformity. A more logical alternative can be projected from the following question: Why resect and replace when you

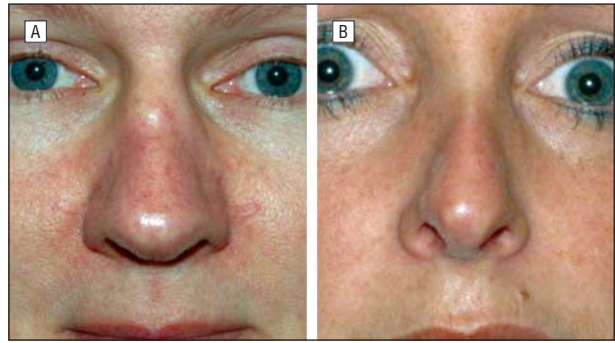

Figure 3. Clinical examples of what can go wrong when a traditional en bloc hump resection maneuver is performed. A, The nasal middle third reveals a light reflex in the midline, which is the prominent caudal margin of the bony dorsum. The interrupted course of shadow on the lateral aspects of the nose break the continuity of the dorsal aesthetic lines. Both irregularities indicate the inferomedial repositioning of the cartilaginous complex, which leads to the distinct inverted-V shade formation. B, Short nasal bones and weak cartilage of the upper lateral cartilages (ULCs) aggravate the result. Note the visible border of the dorsal septum with bilaterally collapsed ULCs in the keystone area positioned underneath the level of the septum (as indicated in Figure 2). The shade formation accentuates the minimal dorsal width.

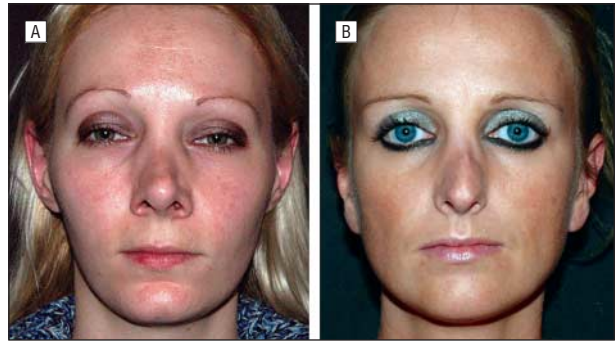

Figure 4. Clinical examples of highly conspicuous inverted-V deformities after traditional en bloc hump resections (second opinions not included in this study). Both patients had short nasal bones. In both cases, the inverted-V deformity is aggravated by overresection and the lack of adequate preventive maneuvers (eg, spreader grafts). Note the extensive makeup of the eyes, by which both patients try to distract the observer's attention from their nose. A, The distinct change between light and shadow accentuates the difference in height between the bony vault and the collapsed cartilaginous complex. B, One step worse: palpable and visible open roof deformity.

can preserve original structures? A promising alternative for reduction of an overprojected nasal dorsum would, therefore, be a corrective approach in 2 planes instead of a transversely positioned en bloc resection. We performed parasseptal vertical incisions to separate the entire ULC from the septum. This exposed a narrow septum, which was deprojected in a transverse plane by taking off a strip of cartilage along its anterior border (**Figure 5**). By using this specific technique, the transverse components of both ULCs could remain fully intact (**Figure 6**). If indicated, nasal dorsal width was then either reduced by resecting vertically positioned strips of the ULCs or further augmented with well-known, previously mentioned grafting modalities. Various researchers already described this technique using different terms.^{2,3,7,8} We refer to this technique as the *split hump technique* (SHT), a term that was introduced by Daniel.⁹

We performed the SHT in 97 patients with an overprojected nasal dorsum. In this article, we describe our philosophy of the SHT and report on its aesthetic and

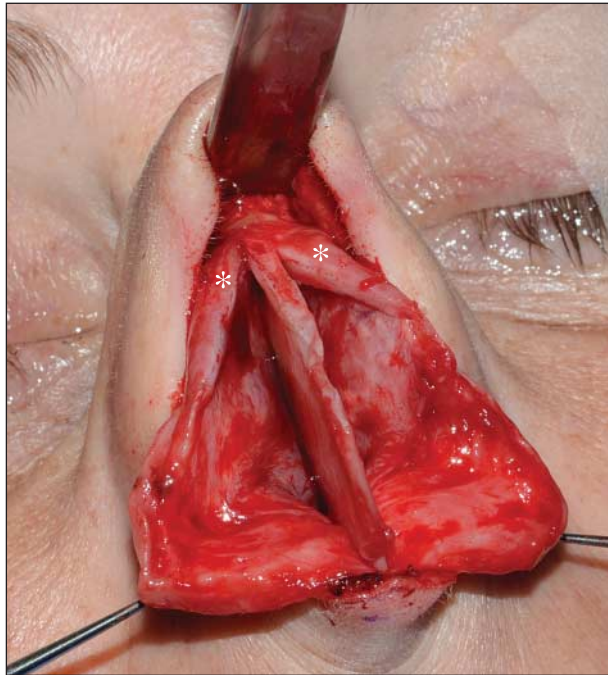


Figure 5. Intraoperative view of the split hump technique after separation of the upper lateral cartilages (ULCs) from the septum. The asterisks indicate the completely preserved transverse components of the ULCs. Note the bilaterally released mucoperichondrium to avoid any traumatization to the mucosal inner lining, which could lead to postoperative cicatricial web formation or narrowing of the internal nasal valve.

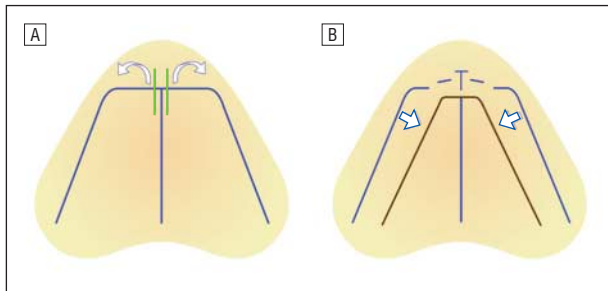


Figure 6. Schematic visualization of the split hump technique. Inferomedial repositioning of the upper lateral cartilages (ULCs) is omitted successfully by preserving the transverse components of the ULCs. A, The ULCs are separated by means of paraseptal vertical incisions on either side of the septum (curved arrows). This produces a narrow septum with 2 completely preserved ULCs. B, Next, the height of the septum is corrected by transverse excision of the dorsal septum. This may be combined with vertical excision of the ULCs to reduce the dorsal width or additional maneuvers to increase the dorsal width. The lateral segments of the ULCs are then repositioned to the new edge of the dorsal septum (straight arrows). These maneuvers are visualized in Figures 7 and 8.

functional relationships by using statistically analyzed data collected using a short, practical questionnaire designed in our center by one of us (P.J.F.M.L.).

METHODS

Ninety-seven patients who underwent aesthetic rhinoplasty between January 1, 2007, and December 31, 2011, were included in the study. The inclusion criteria were as follows: (1) patients had to pay for the surgery, indicating that the reason for surgery was mainly aesthetic; (2) a significant dorsal hump had to be removed during surgery by means of the SHT;

and (3) complete follow-up with functional and aesthetic feedback preoperatively and postoperatively had to be collected. Written informed consent was obtained from all the patients. All the surgical procedures were performed by one of us (P.J.F.M.L.).

For subjective outcome assessment, we used a short and practical-designed questionnaire at the outpatient department before and after surgery. This questionnaire, based on the earlier validated questionnaires of Stewart et al¹⁰ and Alsarraf et al,¹¹ was introduced in a previous article. The questionnaire was subdivided into 2 fields of interest: functional and aesthetic. The functional subject area investigated patient perception of nasal patency. The aesthetic survey items analyzed perception of body image in relation to nasal appearance. Patients were asked to answer 5 questions, scored on a 5-point Likert scale, for both fields of interest (**Table 1**). The minimum score for each question was 1 point, and the maximum score was 5 points. The single score of every question, and the sum scores of the questions in both fields of interest, were then analyzed and compared before and after surgery. Furthermore, visual analog scales (VASs) were used before and after surgery to investigate nasal patency for each side separately (functional score: 0=very bad to 10=very good) and nasal appearance (aesthetics score: 0=very ugly to 10=very nice). For statistical analysis, we applied a *t* test for paired data using a commercially available software program (SPSS, version 16.0 for Windows; SPSS Inc).

SURGICAL TECHNIQUE

The SHT for reduction of the overprojected nasal dorsum can be performed using either a closed or endonasal approach. In the Department of Otolaryngology/Head and Neck Surgery, Center for Facial Plastic and Reconstructive Surgery, Diakonessen Hospital Zeist, we tend to use an open approach because this provides wide exposure of the dorsum, thereby allowing additional diagnosis and increasing surgical control.

STEP 1: PREPARATION

1. Retraction of the skin soft-tissue envelope in the avascular supraparichondrial plane.
2. Meticulous elevation of the mucoperichondrium on both sides of the anterior septum to avoid a mucosal wound when reducing the dorsum. This will result in a more controlled and faster healing process (Figure 5).

STEP 2: SHT

1. A vertically positioned No. 15 blade is inserted underneath the cartilaginous vault, carefully avoiding traumatization of the mucoperichondrial flaps in this area (Figure 6).
2. The entire ULCs are bilaterally separated from the septum using paraseptal vertical incisions.
3. Dorsal height is reduced in a transverse plane using straight scissors or a No. 15 blade.
4. Judicious reduction of the bony dorsum is done using a rasp rather than an osteotome. Subsequently, the underlying cartilage is resected or repositioned in a controlled manner.

Table 1. Likert Scale Questions^a Used in the Short, Practical-Questionnaire to Compare Patient Preoperative and Postoperative Evaluations

Question	Score				
	1 (Not at All/Never)	2	3	4	5 (Very Much/Often)
F1: Do you feel a swelling inside in your nose?	<input type="checkbox"/>	<input type="checkbox"/>	<input type="checkbox"/>	<input type="checkbox"/>	<input type="checkbox"/>
F2: Do you feel a nasal blockage or obstruction?	<input type="checkbox"/>	<input type="checkbox"/>	<input type="checkbox"/>	<input type="checkbox"/>	<input type="checkbox"/>
F3: Do you have difficulties with nasal breathing?	<input type="checkbox"/>	<input type="checkbox"/>	<input type="checkbox"/>	<input type="checkbox"/>	<input type="checkbox"/>
F4: Do you have difficulties with sleeping?	<input type="checkbox"/>	<input type="checkbox"/>	<input type="checkbox"/>	<input type="checkbox"/>	<input type="checkbox"/>
F5: Do you have problems getting enough air through your nose during physical exercise?	<input type="checkbox"/>	<input type="checkbox"/>	<input type="checkbox"/>	<input type="checkbox"/>	<input type="checkbox"/>
AE1: Are you concerned about the appearance of your nose?	<input type="checkbox"/>	<input type="checkbox"/>	<input type="checkbox"/>	<input type="checkbox"/>	<input type="checkbox"/>
AE2: Does this concern bother you often?	<input type="checkbox"/>	<input type="checkbox"/>	<input type="checkbox"/>	<input type="checkbox"/>	<input type="checkbox"/>
AE3: Does this concern affect your daily life (eg, your work)?	<input type="checkbox"/>	<input type="checkbox"/>	<input type="checkbox"/>	<input type="checkbox"/>	<input type="checkbox"/>
AE4: Does this concern affect your relationship with others?	<input type="checkbox"/>	<input type="checkbox"/>	<input type="checkbox"/>	<input type="checkbox"/>	<input type="checkbox"/>
AE5: Do you feel stressed by the appearance of your nose?	<input type="checkbox"/>	<input type="checkbox"/>	<input type="checkbox"/>	<input type="checkbox"/>	<input type="checkbox"/>

^aFive functional questions examine patient nasal patency (F1-F5), and 5 aesthetic questions investigate the subjective perception of body image in relation to nasal appearance (AE1-AE5).

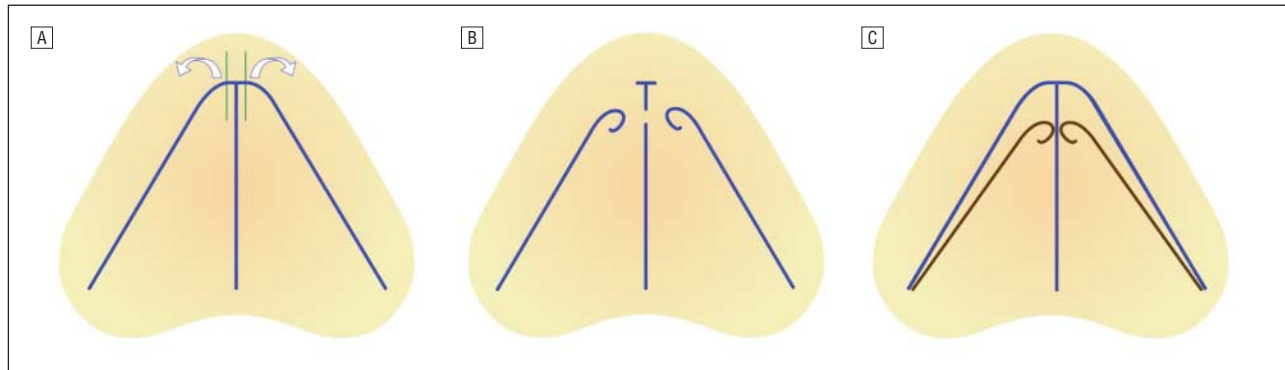


Figure 7. Schematic illustration of the split hump technique combined with autospreader grafts. This corrective modality can be applied in patients with moderate insufficiency of dorsal width and adequate stability of the cartilage (Figure 8B). A, Paraseptal vertical incisions on either side of the septum separate the upper lateral cartilages (ULCs) from the septum. B, Transverse excision of the dorsal septum lowers the dorsal height. C, The lateral segments of the ULCs are turned in and sutured to the new edge of the dorsal septum.

5. For correction of nasal width, each ULC can be addressed separately.

6. The ULCs are aligned adjacent to the lowered anterior border of the septum.

7. Anchorage is performed using at least two 5-0 polydioxanone mattress sutures running through the ULCs and the septum. The sutures need to be placed symmetrically to avoid irregular vectors of pull leading to aesthetic or functional confinement.

STEP 3: ADDITIONAL MANEUVERS

In instances of an asymmetrical nose, inadequate dorsal width, or functional impairment of the midvault, the SHT can be combined with additional grafting techniques. The options include unilateral or bilateral application of additional spreader grafts, implementation of autospreaders (formed by turning in the ULCs before suture fixation), or a combination (**Figure 7** and **Figure 8**). Improvement of nasal patency was additionally addressed by septoplasty or lateralization of the inferior turbinates, when indicated.

RESULTS

This study included 81 women and 16 men aged 17 to 66 years (mean age, 34.3 years; male to female ratio, 1 to 5.1). All the patients showed an overprojected nasal dorsum, which was in all cases reduced using the SHT. Three patients had previously undergone rhinoplasty in another hospital. Minimum follow-up was 1 year.

Additional dorsum maneuvers, as described in the “Surgical Technique” section, were introduced in 51 rhinoplasties. Spreader grafts were used in 45 operations (27 unilateral and 18 bilateral). Autospreader grafts were constructed in 6 patients, with unilateral autospreader application in only 1 patient. A combination of spreader grafts and autospreaders was performed in 2 procedures.

Comparison of the preoperative and postoperative scores collected from the 5 functional and 5 aesthetic Likert scale questions showed a highly significant improvement in every single question (Table 1). No score remained constant or worsened after performance of the SHT (**Table 2**). Patient subjective evaluation of nasal patency improved significantly in all questioned aspects. The sum score of all

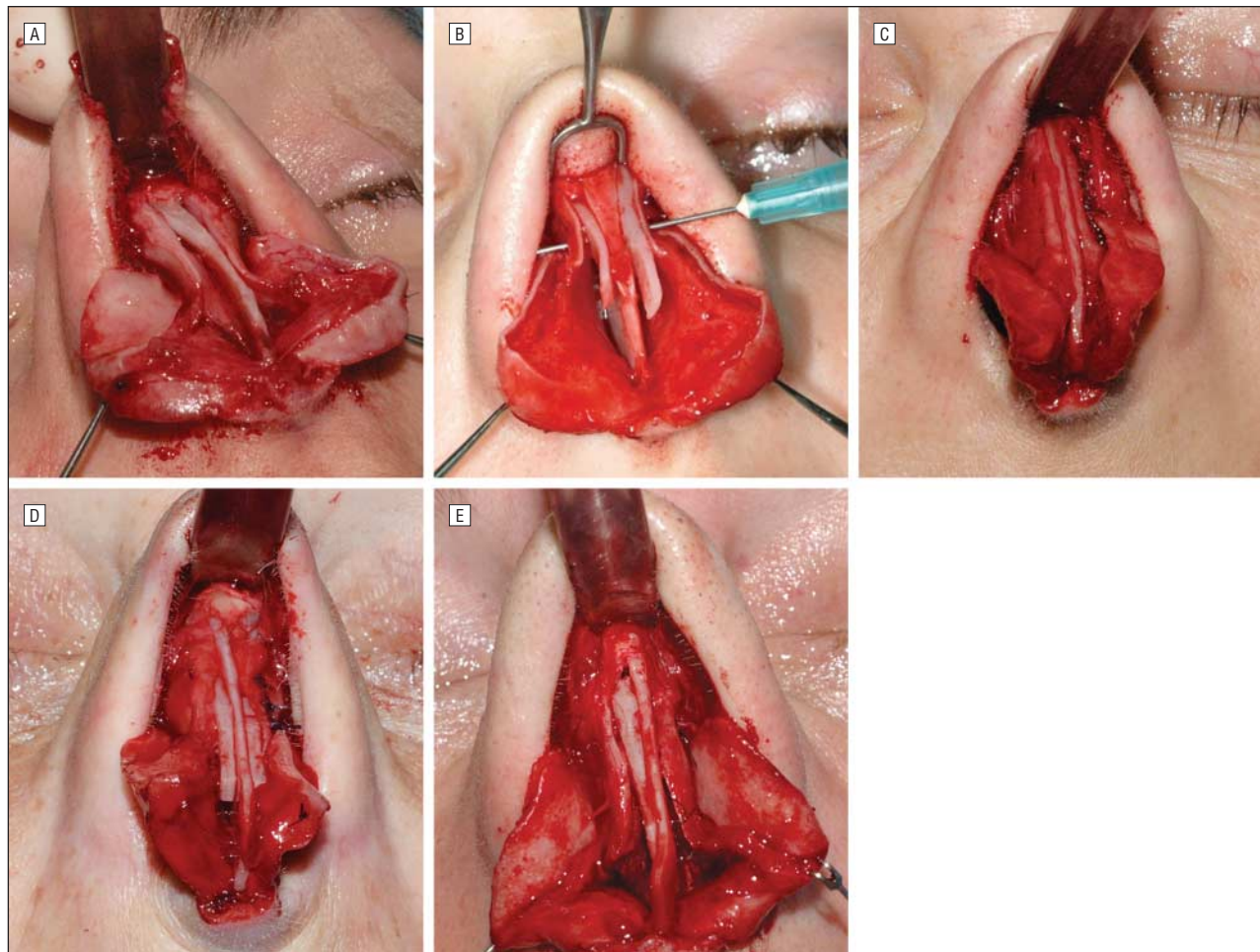


Figure 8. Clinical examples of possible variations of the split hump technique. A, Patients with adequate dorsal width only need an incremental reduction in dorsal height. A strip of cartilage is resected from the septum. The unaltered upper lateral cartilages (ULCs) can then be aligned and sutured to the new anterior border of the septum. B, Congenital absence of both transverse components of the ULCs. The patient showed a narrow midnasal third and a compromised airway. Opening of the internal valve and adequate dorsal width were established using bilaterally placed spreader grafts. C, Reduction of a high narrow dorsum allows application of the ULCs for increased dorsal width. In accordance with Figure 7, both lateral components of the ULCs were turned in and anchored as autospreaders. This variation enables the augmentation of dorsal width in patients with adequate length and stability of the transverse components of the ULCs. D, Combination of both additional maneuvers (intraoperative view of case 1): to ensure a continuous dorsal width, we combined cephalically formed autospreaders with caudally placed spreader grafts on both sides of the septum. E, In the case of an asymmetrical nose, the necessary extension of augmentation can vary on both sides of the septum. Alternative combination of both additional maneuvers: unilateral placement of a spreader graft (right side) and contralateral application of an autospreader.

functional questions decreased from 9.154 to 6.351 ($P < .001$). The postoperative perception of body image in relation to nasal appearance improved even stronger, with a decrease in the sum score of the aesthetics questions from 13.897 to 6.825 ($P < .001$).

Analysis of the subjective evaluation of nasal passage for each side using VASs revealed a highly significant increase on both sides (left: from 6.994 to 8.065, $P < .001$; right: from 7.093 to 8.118, $P < .001$). The aesthetic VAS in all the patients improved from 3.346 to 7.782 ($P < .001$) (Table 2). The graphic illustration of this amendment revealed a gaussian curve of normal distribution with a mean (SD) of 4.48 (1.93) (**Figure 9**).

COMMENT

The nasal dorsum is composed of a unified osseocartilaginous composite, which can be subdivided into a cranially positioned bony vault and a caudal cartilaginous vault, which extends under the bony segment. In most

cases, the hump is far more cartilaginous than bony. The cartilaginous complex is composed of the septum and the ULCs. This complex is not a septum with bilaterally juxtaposed ULCs but a single anatomical entity from a common embryologic origin.^{9,12} The mechanical characteristics of the cartilaginous complex mainly depend on the strength and thickness of the cartilage, which can be diverse on the basis of sex, age, ethnicity, and previous trauma (iatrogenic or accidental). The nasal bones, the bony septum, and the cartilaginous complex together establish the K-area. The term *keystone* is derived from roman arch architecture describing the topmost central stone, which exclusively ensures stability to the entire formation. Likewise, the complete K-area in the nose is of critical importance for maintaining the structural stability of the nasal dorsum.

Taking down the osseocartilaginous composite includes resection of the K-area. The consequence is collapse of the adjacent structures, leading to inferomedial repositioning of the remaining ULCs (Figure 1). As the

Table 2. Preoperative and Postoperative Scores on the Short, Practical Questionnaire^a

Question	Preoperative Scores	Postoperative Scores
Functional		
F1	1.773	1.133
F2	1.721	1.206
F3	1.989	1.319
F4	1.670	1.175
F5	2.000	1.299
Subtotal	9.154	6.351
Aesthetics		
AE1	3.464	1.649
AE2	3.268	1.557
AE3	2.536	1.237
AE4	2.247	1.216
AE5	2.392	1.216
Subtotal	13.897	6.825
10-Point VAS		
Function of left side	6.994	8.065
Function of right side	7.093	8.118
Aesthetics	3.346	7.782

Abbreviation: VAS, visual analog scale.

^a $P < .001$ for all. Five functional questions investigated patient perception of nasal patency (F1-F5). Five aesthetic questions analyzed patient perception of body image in relation to nasal appearance (AE1-AE5). The possible score range for each question was 1 to 5. Statistical analysis was performed on each single question and on the summary scores of each field of interest.

inclining lateral components of the ULCs are of insufficient length for bridging the gap bilaterally to the dorsal septum, this leads on the outside to a conspicuous inverted-V deformity (Figure 2). This deformity is based on a distinct formation of shadow, which is caused by a difference in height between the caudal margin of the bony dorsum and the lowered inferomedially malpositioned cartilaginous components of the cartilaginous dorsum (Figure 3). Furthermore, en bloc hump removal can easily result in overresection of the bony vault, generating an open roof. Such an extensive reduction makes infrafractures of the bony segments an additional prerequisite for compensation, which further weakens the complete K-area (Figure 4). Especially patients with short nasal bones and long weak ULCs have no means of compensating for the risk of a conspicuous inverted-V deformity after traditional humpectomy.

The best treatment strategy for correction of the overprojected dorsum is avoidance. In more specific terms, this means avoidance of an open roof, avoidance of extensive destabilization of the K-area, and, subsequently, avoidance of an inverted-V deformity. The concept of avoidance resulted in widespread application of diverse preventive techniques, which were combined with traditional hump removal on a regular basis.¹³ Surgeons applied spreader grafts or their variations (eg, autospreaders) as an integral part of the en bloc hump reduction for the past 3 decades.²⁻⁶ These techniques have proved to be helpful in aesthetic corrections of the middle third of the nose and in reconstruction of the internal valve after composite humpectomy.

Could there be another manner to reduce the dorsum and avoid the complication of a weakened K-area? A com-

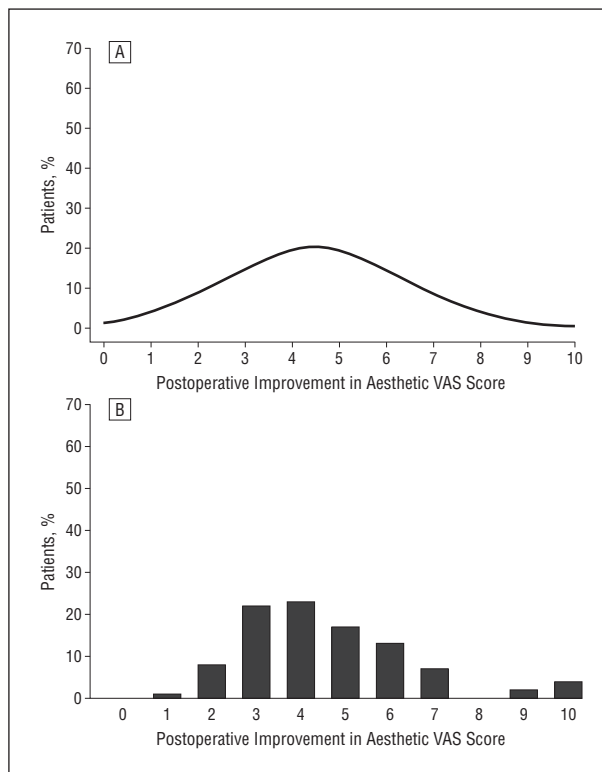


Figure 9. This figure is a graphic illustration of the postoperative improvement in the aesthetic visual analog scale (VAS) score. To substantiate our philosophy of the split hump technique, we performed statistical analysis of information gathered by a set of questions and functional and aesthetic VASs comparing the preoperative and postoperative situation. The figure reveals a gaussian curve (A) of normal distribution around a mean (SD) improvement score of 4.48 (1.93) points after rhinoplasty.

ination of traumatizing resection of the dorsum with the additional imperative of structural grafts might not be the best solution for the challenge of correcting an overprojected dorsum. An alternative concept of avoidance is based on preservation of the K-area anatomy. This implies only a judicious reduction of the dorsal height and optional modifications of the dorsal width in a step-by-step procedure. Approaching an overprojected dorsum by initially saving the entire anatomy instead of resecting the osseocartilaginous composite is a paradigm change. Analogous to nasal tip surgery, the motto for dorsal surgery should be to “preserve and conserve” instead of “resect and regret.” A key benefit of the SHT lies in the fact that no bridges are burned. Because no cartilage is initially excised, the stability of the K-area is far less compromised. Reduction of the bony dorsum using a rasp rather than an osteotome avoids an open roof deformity and abundant trauma to the tissue. Rasping exposes the underlying cartilaginous hump that extends underneath the bone and can then be addressed by precise separation from the septum. Such a stepwise approach allows a high level of precision and controlled preservation of the transverse components of the ULCs, avoiding bilateral gap formation and subsequent inferomedial repositioning of the ULCs. In the case of a preexisting adequate width, reduction of dorsal height is the only procedure necessary, with no modification of the ULCs (Figure 8A and **Figure 10**). In addition to a measured reduction in dorsal width, the broad spectrum of varia-

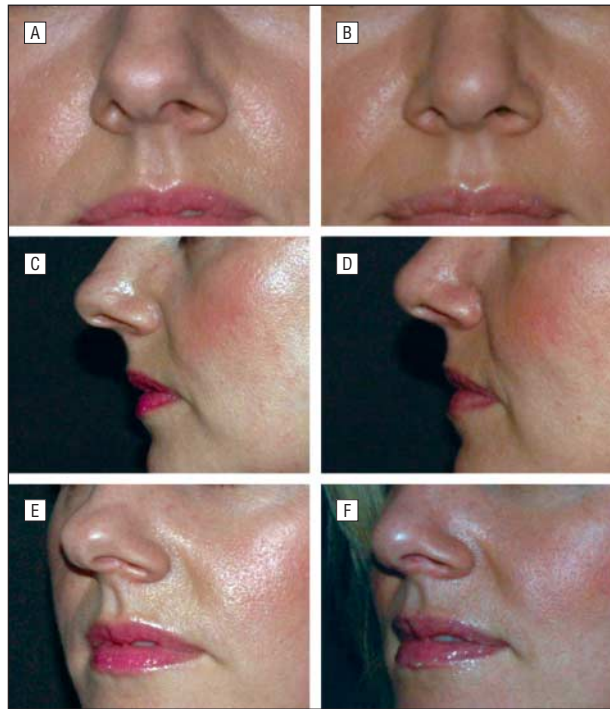

Figure 10. Preoperative and postoperative photographs. Preoperative (A, C, and E) and postoperative (B, D, and F) views in a 40-year-old woman with a prominent dorsal hump, an accentuated supratip break, an overprojected nasal tip, fullness of the lateral crura, and a rightward deviation. The operative goals were to reduce the dorsal hump, deproject and refine the tip, and establish symmetry of the dorsal aesthetic lines. Surgical correction of the dorsum included separation of the upper lateral cartilages (ULCs) in accordance with the split hump technique, and reduction in dorsal height by resecting a strip of septal cartilage without modification to the width of the ULCs (Figure 8A). Preoperative scores were as follows: functional questions 1 to 5: 3, 1, 1, 1, and 1, respectively; aesthetic questions 1 to 5: 4, 4, 3, 4, and 3, respectively; visual analog scale (VAS) function on the left side: 7; VAS function on the right side: 7; VAS aesthetics: 1. Postoperative scores were as follows: functional questions 1 to 5: 2, 1, 1, 1, and 1, respectively; aesthetic questions 1 to 5: 2, 1, 1, 1, and 1, respectively; VAS function on the left side: 8; VAS function on the right side: 8; and VAS aesthetic: 8.

tions of the SHT (Figure 8B-E), using additional maneuvers, allows high precision and control for augmentation of dorsal width. Application of autospreaders or spreader grafts allows incremental control of dorsal width (Figure 8B-D and **Figure 11**). Also, asymmetries can be addressed properly as a further variation of the SHT (Figure 8E).

In conclusion, preservation of the ULCs extends the surgeon's options. The SHT is an effective method to avoid inverted-V deformity, and it entails the option to use pre-existing tissue for augmentation and strengthening of dorsal width and K-area. The judicious reduction in dorsal height bears only little risk of overresection. The high precision in correction of the dorsal width prevents inferomedial repositioning of the ULCs. Consequently, on the visible outside of the nose, the transition of light and shadow remains smooth in the K-area, whereas the dorsal aesthetic lines stay uninterrupted. Furthermore, by preserving the middle vault anatomy, including protection of an intact mucoperichondrial lining, and by adding additional structural grafts to the valve area, there is less risk of postoperative pinching and a high chance of an increase in nasal breathing after SHT.

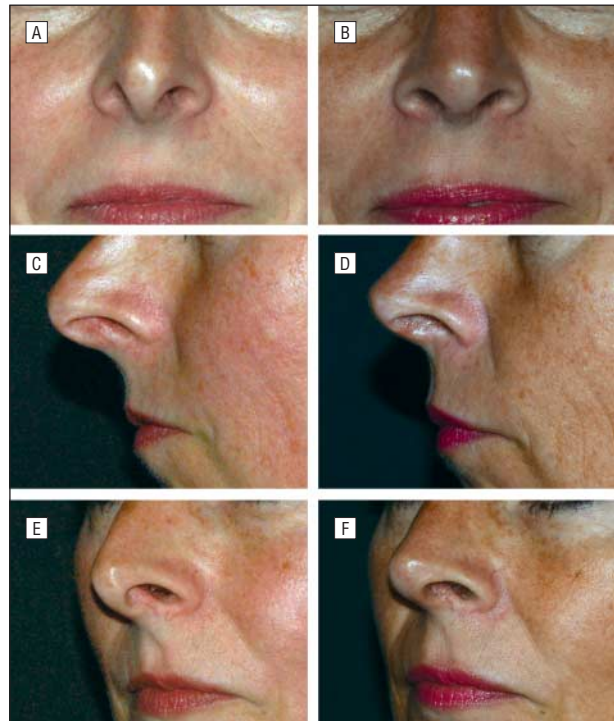

Figure 11. Preoperative and postoperative photographs. Preoperative (A, C, and E) and postoperative (B, D, and F) views in a 45-year-old woman with an overprojected nose, a high nasal dorsum, and a septal deviation to the right. The operative goals were to improve nasal patency, re-create symmetry of the dorsal aesthetic lines, decrease projection of the dorsum and tip, and reduce the degree of columella show. Surgical correction of the dorsum involved incremental reduction of the dorsum using the split hump technique and augmentation of nasal width in the middle third of the nose by sandwiching the septum between cranially formed autospreaders and caudally placed spreader grafts using autologous septal cartilage (Figure 8D). Preoperative scores were as follows: functional questions 1 to 5: 3, 1, 3, 4, and 2, respectively; aesthetic questions 1 to 5: 4, 4, 4, 4, and 4, respectively; visual analog scale (VAS) function on the left side: 5; VAS function on the right side: 4; and VAS aesthetic: 2. Postoperative scores were as follows: functional questions 1 to 5: 2, 1, 1, 1, and 1, respectively; aesthetic questions 1 to 5: 1, 1, 1, 1, and 1, respectively; VAS function on the left side: 9; VAS function on the right side: 9; and VAS aesthetic: 8.

We consider the SHT to be a safe and powerful approach offering multiple solutions for reduction of an overprojected dorsum. To substantiate this philosophy, we confronted patients with the subjective outcome assessment (using a short, practical-designed questionnaire) to compare patient estimations preoperatively and postoperatively. All questions regarding nasal patency or perception of body image in relation to nasal appearance improved significantly after the SHT ($P < .001$). The graphics in Figure 9 summarize the perioperative improvement in the aesthetic VAS score. The graph highlights patients' broad acceptance and appreciation of the cosmetic results, as we could prove by means of statistics. The fact that the curve depicts the shape of a normal distribution around a mean of 4.48 points of improvement on a scale of 10 indicates a realistic outcome and strengthens the findings. We believe that the SHT could be of benefit to rhinoplasty surgeons who deal with the overprojected nasal dorsum.

The adequate reduction of a prominent dorsum is a major determinant for success in most patients who undergo aesthetic rhinoplasty. Traditional en bloc humpec-

tomy maneuvers bear a high risk destabilizing the K-area region. To avoid subsequent inferomedial repositioning of the ULCs and an inverted-V deformity, additional structural grafts (eg, spreader grafts) have gradually become routine since the 1980s.

The SHT is based on preservation of the entire ULCs during deprojection of the nasal dorsum. Dorsal height and dorsal width are addressed separately, allowing a high level of precision and control. Additional combination with established structural maneuvers broadens the surgeon's options for augmenting and strengthening dorsal width and the K-area. Statistical analysis of subjective patient data strengthened our belief that the SHT is a safe and powerful method that provides adequate aesthetic and functional results. Equivalent to nasal tip surgery, "preserve and conserve" instead of "resect and regret" should lead to a paradigm change in nasal dorsum surgery in a larger group of rhinoplasty surgeons.

Accepted for Publication: April 11, 2012.

Correspondence: Peter J. F. M. Lohuis, MD, PhD, Department of Otolaryngology/Head and Neck Surgery, Center for Facial Plastic and Reconstructive Surgery, Diaconessen Hospital Zeist, Prof Lorenzlaan 76, 3707 HC Zeist, the Netherlands.

Author Contributions: Dr Bran had full access to all the data in the study and takes responsibility for the integrity of the data and the accuracy of the data analysis. *Study concept and design:* Lohuis and Bran. *Acquisition of data:* Lohuis and Bran. *Analysis and interpretation of data:* Lohuis, Faraj-Hakim, Knobbe, and Duivesteijn. *Drafting of the manuscript:* Lohuis, Faraj-Hakim, Knobbe, and Bran. *Critical revision of the manuscript for important intellectual content:* Lohuis, Duivesteijn, and Bran. *Statistical analysis:* Lohuis, Faraj-Hakim, Knobbe, and

Duivesteijn. *Administrative, technical, and material support:* Lohuis and Bran. *Study supervision:* Bran.

Financial Disclosure: None reported.

Previous Presentation: This study was presented in part at the International Federation of Facial Plastic Surgery Societies Nose & Face World meeting; May 12, 2012; Rome, Italy.

REFERENCES

1. Rohrich RJ, Muzaffar AR, Janis JE. Component dorsal hump reduction: the importance of maintaining dorsal aesthetic lines in rhinoplasty. *Plast Reconstr Surg.* 2004;114(5):1298-1312.
2. Byrd HS, Meade RA, Gonyon DL Jr. Using the autospreader flap in primary rhinoplasty. *Plast Reconstr Surg.* 2007;119(6):1897-1902.
3. Constantian MB, Clardy RB. The relative importance of septal and nasal valvular surgery in correcting airway obstruction in primary and secondary rhinoplasty. *Plast Reconstr Surg.* 1996;98(1):38-58.
4. Gruber RP, Park E, Newman J, Berkowitz L, Oneal R. The spreader flap in primary rhinoplasty. *Plast Reconstr Surg.* 2007;119(6):1903-1910.
5. Gruber RP, Perkins SW. Humpectomy and spreader flaps. *Clin Plast Surg.* 2010;37(2):285-291.
6. Sheen JH. Spreader graft: a method of reconstructing the roof of the middle nasal vault following rhinoplasty. *Plast Reconstr Surg.* 1984;73(2):230-239.
7. Walter C. *Plastisch-chirurgische Eingriffe im Kopf-Hals-Bereich.* Stuttgart, Germany: Georg Thieme Verlag KG; 1997.
8. Kim CH, Jung DH, Park MN, Yoon JH. Surgical anatomy of cartilaginous structures of the Asian nose: clinical implications in rhinoplasty. *Laryngoscope.* 2010;120(5):914-919.
9. Daniel RK. *Mastering Rhinoplasty.* 2nd ed. New York, NY: Springer; 2010.
10. Stewart MG, Witsell DL, Smith TL, Weaver EM, Yueh B, Hannley MT. Development and validation of the Nasal Obstruction Symptom Evaluation (NOSE) scale. *Otolaryngol Head Neck Surg.* 2004;130(2):157-163.
11. Alsarraf R, Larrabee WF Jr, Anderson S, Murakami CS, Johnson CM Jr. Measuring cosmetic facial plastic surgery outcomes: a pilot study. *Arch Facial Plast Surg.* 2001;3(3):198-201.
12. van Loosen J, Verwoerd-Verhoef HL, Verwoerd CD. The nasal septal cartilage in the newborn. *Rhinology.* 1988;26(3):161-165.
13. Camirand A, Doucet J, Harris J. Nose surgery: how to prevent a middle vault collapse: a review of 50 patients 3 to 21 years after surgery. *Plast Reconstr Surg.* 2004;114(2):527-534.